ODONTOGENTIC INFECTIONS

- Peter A. Vellis, D.D.S.

In a state of homeostasis, there is a balance between the three.

PROGRESSION OF ODONTOGENIC INFECTIONS

Infection Spread Determinants

- Location, location , location
  1. Source
  2. Bone density
  3. Muscle attachment
  4. Fascial planes

- "The Path of Least Resistance"

Odontogentic Infections

- Common occurrences due primarily to caries and periodontal disease.
- Odontogentic infections can extend to potential fascial spaces.

Progression of Odontogenic Infections

- Periapical
- Periodontal
- Soft tissue involvement
  - Determined by perforation of the cortical bone in relation to the muscle attachments
- Cellulitis- acute, painful, diffuse borders
- Abscess- chronic, localized pain, fluctuant, well circumscribed.

INFECTIONS

Classic signs and symptoms:

Dolor- Pain
Tumor- Swelling
Calor- Warmth
Rubor- Redness
Loss of function
- Trismus
- Difficulty in breathing, swallowing, chewing

Severity of the Infection

- Complete History
  - Chief Complaint
  - Onset
  - Duration
  - Symptoms

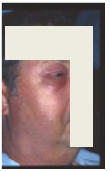

Severity of the Infection

- How the patient feels- Malaise
- Previous treatment
- Self treatment
- Past Medical History
- Review of Systems

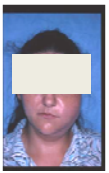

Physical Examination

- Vital Signs
  - Temperature- systemic involvement >101 F
  - Blood Pressure- mild elevation
  - Pulse- >100
  - Increased Respiratory Rate- normal 14-16
  - Lymphadenopathy

Fascial Planes/Spaces

- Potential spaces for infectious spread between loose connective tissue
- Planes compartmentalize structures (muscle, nerve, vessels)

Fascial Planes/Spaces

- Primary spaces
  - Canine
  - Buccal
  - Submandibular
  - Submental
  - Sublingual
  - Vestibular

Fascial Planes/Spaces

- Secondary spaces become involved via spread from primary space infections
  - Masseteric
  - Pterygomandibular
  - Infratemporal
  - Superficial/Deep Temporal
  - Lateral/Retropharyngeal
  - Prevertebral
  - Periorbital

Base of the Upper Lip

Source – Maxillary incisors

- Upper lip swollen
- Alar base and nasal tip elevated
- Labial vestibule obliterated

Palatal Swelling

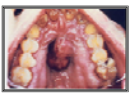

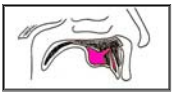

Anatomic Location:

Between the palatal cortical bone and mucoperiosteum

Canine Space

Anatomic Location:

- Superiorly by the levator muscles
- Anteriorly by the orbicularis oris muscle
- Posteriorly by the buccinator muscle and zygomaticus muscle.

Canine Space

Clinical Presentation:

- Obliterated nasolabial fold
- Edema of upper lip and lower eye lid
- Swelling of the vestibule

Periorbital Space

Lies between the orbicularis oculi and the orbital septum

Periorbital (Preseptal) Space

Clinical Presentation: Redness and swelling of the eyelid, may obstruct vision

INFECTIOUS SWELLINGS OF THE DENTO-ALVEOLAR RIDGES (VESTIBULAR ABSCESS)

- Anatomic location
- Signs and symptoms
- Odontogenic origin
- Pattern of spread
- Risk

LOW

MANDIBULAR FACIAL VESTIBULE

- Anatomic location
- Signs and symptoms
- Odontogenic origin
- Pattern of spread
- Risk

LOW

SPACE OF THE BODY OF THE MANDIBLE (SUBPERIOSTEAL ABSCESS)

- Anatomic location
- Signs and symptoms
- Odontogenic origin
- Pattern of spread
- Risk

LOW

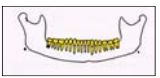

SUBMENTAL SPACE

Anatomic location
Signs and symptoms
Odontogenic origin
Pattern of spread
Risk

MOD

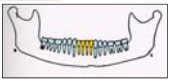

Submental space

Odontogenic origin: Mandibular incisors, chin, lower lip or tip of tongue.

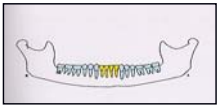

Submental space

- Located between the mylohyoid and platysma superio-inferiorly
- Between the diverging anterior bellies of the digastric muscles laterally.
- Communicates with submandibular space posteriorly.

Submental Space Infection

Submental space

Sign and symptoms:

Swollen area under the chin, in the middle third of the mandible. They may have difficulty swallowing and elevation of the tongue is usually not seen.

Patterns of spread:

May spread to submandibular spaces unilaterally or bilaterally and then to the parapharyngeal spaces.

Move inferiorly to involve fascial planes of the neck.

Move superiorly and involve the sublingual space.

Submental Space Infection

Sublingual space

- Superior to the mylohyoid muscle and inferior to the mucosa of the floor of the mouth.
- Lingual surfaces of the mandible are this space's lateral and anterior borders.
- Hyoglossus, geniohyoid and genioglossus muscles can divide this space into two sections

Sublingual space

Signs and symptoms: usually there is no external swelling, patients may experience discomfort during swallowing and may have elevation of the tongue.

Patterns of spread:

- Posterio-inferiorly into the submandibular space.
- Posterio-laterally into the parapharyngeal space or pterygomandibular space.

Sublingual space

Odontogenic origin: Usually caused by infection involving any mandibular tooth(incisors, canines, premolars and mesial roots of the first molars) that has its apex above the mylohyoid muscle.

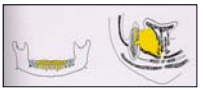

Sublingual Space Infection

Sublingual Space Infection

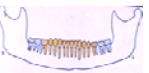

Submandibular Space Infection

Submandibular space

- Lies inferior to the mylohyoid muscle.
- Located medial to the body of mandible.
- Medial boundaries are mylohyoid and hypoglossus muscles
- Lateral borders are body of mandible and platysma.
- Anterior and posterior bellies of digastric muscle and the lower border of the mandible form the **submandibular triangle.**

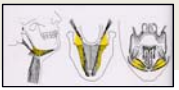

Submandibular space

Signs and symptoms

- Swelling of the submandibular region
- Feels hard due to localization of the pus deep to the platysma.
- There is a limited range of opening due to interference with muscle activities. Patients may have a higher potential for developing a systemic spread of this infection.

Submandibular space

Patterns of spread:

- Sublingual space by extending around the posterior border of the mylohyoid or by perforating the mylohyoid.
- Submandibular space on the opposite side.
- Fascial planes of the neck by extending inferiorly.
- Parapharyngeal or pterygomandibular spaces by extending posteriorly.
- Deep temporal space by extending superio-posteriorly.

Submandibular space

Odontogenic origin:

- Most frequent causes of this space infection are the dental abscesses, pericornitis of mandibular molars and post surgical infections.
- Dental abscess which penetrate the lingual cortical plate below the attachment of the mylohyoid muscle drain into this space.
- Soft tissue infections in the retromolar area may spread directly into this space.

Ludwig's angina

Anatomic location: It is a massive bilateral cellulites involving mandibular fascial spaces including the sublingual, submandibular and submental spaces. Usually the pharyngeal spaces become involved

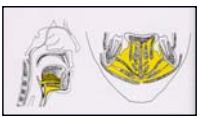

Ludwig's angina

Sign and symptoms:

Swelling may displace the tongue upwards and backward.

The external clinical appearance is an indurated massive bilateral submandibular swelling, which extends down the anterior part of the neck to the clavicles.

Patients frequently have fever up to 104°F. Swallowing is difficult, breathing becomes progressively more labored and drooling is evident.

Pattern of spread:

- Spread to the mediastinum via fascial planes in the neck.
- Cause glottic edema and lead to respiratory obstruction

Ludwig's angina

Odontogenic origin:

- Infection from mandibular teeth can spread to the submental, sublingual and submandibular spaces.
- The spread from any of the above spaces to all of them constitutes clinical syndrome termed Ludwig's angina.

Ludwig's angina is an acute medical emergency requiring immediate hospitalization.

Ludwigs angina

SWELLINGS OF THE LATERAL FACE AND CHEEK

SWELLINGS OF THE LATERAL FACE AND CHEEK

- Maxillary Buccal Vestibule
- Buccal space
- Masseteric space
- Deep temporal space
- Superficial temporal space
- Parotid space

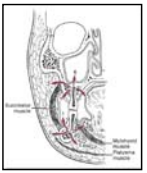

MAXILLARY BUCCAL VESTIBULE

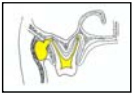

BUCCAL SPACE

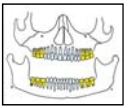

BUCCAL SPACE

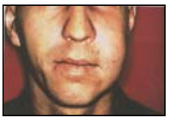

Buccal Space

- Boundaries: Buccinator muscle and/or buccopharyngeal fascia medially. Skin laterally.Pterygomandibular raphe posteriorly.zygomatic arch superiorly. Lower border of the mandible inferiorly. Zygomatic muscle and depressors anteriorly.

MASSETERIC SPACE

Masseteric Space

- Anatomic Location:
  - Lateral surface of the ramus
  - Medial surface of the masseter
- Source of Infection: usually impacted 3rd in which discharge is through the lingual cortical plate. Apices may very close or within space

MASSETERIC SPACE

Temporal Space Infection

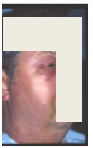

Parotid Space

Parotid Space
Pain, trismus
Medial bulge of posterior lateral pharyngeal wall
Cause—parotitis, sialolithiasis, Sjogren's syndrome

Pharyngeal Spaces

- These infections can become increasingly more severe, with greater complications and morbidity.
- Difficult to treat due the poor blood supply, which diminishes the effectiveness of antibiotics.
- Often require immediate surgical intervention to drain

Pharyngeal Spaces

- If your patient **does not show signs of external swelling,** and yet the signs and symptoms of infection are present (such as trismus, fever, toxicity, etc.), then examination of the pharyngeal area may reveal anterior pillar or pharyngeal area swelling.
- Pharyngeal swelling may ultimately develop from infections of most other fascial spaces.
- Pharyngeal swelling may be due to **odontogenic infections** or it may be the result of **tonsillar inflammation** or **infections of the ear.**

Pterygomandibular Space

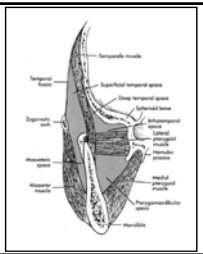

Pterygomandibular Space

- ***Anatomic Location:*** located between the medial surface of the ramus of the mandible and the lateral surface of the medial pterygoid muscle.
- Limited superiorly by the lateral pterygoid which separates this space from the infratemporal space.
- Principal contents are the inferior alveolar neurovascular bundle, the lingual nerve, and the chorda tympani.

Pterygomandibular Space

- *Signs and Symptoms:*
- Moderate to severe trismus.
- Moderate swelling of the tonsillar pillar medially.
- Tenderness can be elicited over the medial aspect of the mandible; however, this symptom would be difficult to recognize in the presence of severe trismus.

Pterygomandibular Space

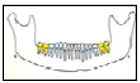

- ***Odontogenic Origin:***
  Pericoronitis associated with partially erupted mandibular third molars.
- **Contaminated needle used or the injection site is not disinfected prior to the injection.**
- **Mandibular second molar infections**

Pterygomandibular Space

- Patterns of Spread:
  - superiorly to involve the temporal spaces
  - antero-medially, then posteriorly to involve parapharyngeal spaces
  - anteriorly and laterally to involve the buccal and submasseteric spaces
  - anteriorly to the infratemporal space
  - anteriorly and inferiorly to the submandibular space.

Pterygomandibular Space

- ***Risk:*** HIGH.
- Regarded as EXTREMELY SERIOUS due to the close proximity to the lateral pharyngeal, retropharyngeal spaces and fascial planes of the neck.
- These infections REQUIRE CLOSE SUPERVISION BY SPECIALISTS and frequently involve hospitalization of the patient.

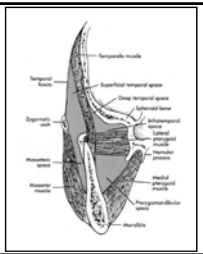

Parapharyngeal Spaces

Signs and Symptoms:

- High fever and significant malaise
- Pain on swallowing is extreme and there is some limitation of opening
- The tonsil and lateral pharyngeal wall are pushed towards the opposite side of the mouth, the uvula is also deflected medially, but the soft palate is not affected.
- There may be slight external swelling

Parapharyngeal Spaces

- ***Patterns of Spread:***
  - inferiorly via carotid sheath and fascial planes of the neck to the mediastinum and pericardium.
  - superiorly to the temporal spaces, base of skull, foramen ovale, and brain.
- ***Risk:*** HIGH. Infections of parapharyngeal spaces are EXTREMELY SERIOUS and require IMMEDIATE hospitalization. Their anatomical location and serious complications require immediate, aggressive, and expert care.

Parapharyngeal Spaces

- ***Odontogenic Origin:*** Most result from infections of the mandibular third molar area.
- Peritonsillar abscesses may also spread to the lateral pharyngeal space.

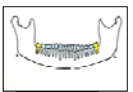

Parapharyngeal Spaces

- Lateral pharyngeal
- Retropharyngeal spaces

Lateral Pharyngeal Space

- *Anatomic location:* A potential cone-shaped space with the skull as the roof, while the apex is closely associated with the carotid sheath below.
- Between the medial pterygoid muscle laterally and the superior constrictor muscle and extends inferiorly to the hyoid bone.
- Below the hyoid bone this space is contiguous with the deep cervical fascia which leads to the mediastinum.

Lateral Pharyngeal Space

Lateral Pharyngeal Space Abscess

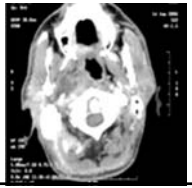

Cervical Spaces

- ***Signs and Symptoms:*** can vary in clinical appearance depending upon the specific fascia or layer involved. The following may be involved:
  - **Brawny swelling of the neck**
  - **Difficulty in swallowing**
  - **Difficulty in breathing**
  - **Obliteration of the sternal notch**
  - **Signs of inflammation** can vary depending upon the depth of the involved space from the skin

Cervical Spaces

- ***Odontogenic Origin:*** Dental infections involving most fascial spaces of the head can spread directly or indirectly to the fascial planes of the neck.
- ***Risk:*** **High.** The seriousness of any infection (regardless of source) involving any of the cervical fascia cannot be over-emphasized and immediate referral to a specialist or hospital is essential!

Peritonsillar Absces

Presentation/Origin

- Peritonsillar Space
  - Fever, malaise
  - Dysphagia, odynophagia
  - "Hot-potato" voice, trismus, bulging of superior tonsil pole and soft palate, deviation of uvula
  - Cause—extension from tonsillitis

Microbiology

- Most infections are Polymicrobial, 5-8 species of bacteria

  Mixed aerobic/anaerobic: 60%

  Anaerobic only: 35%

  Aerobic only: 5%

Aerobic

- Streptococci 70%
- Staphylococci 6%
- Misc 1%
- Rare: Neisseria, Corynebacterium, Haemophilus, Group D Streptococcus

Anaerobic

- G+ cocci 33% (Strepto., Pepto., and Peptostrepto-coccus each 11%)
- G+ rods 15% (Eubacterium and Lactobacillus)
- G- rods 50% (Prevotella(Bacteroides) 34%), Fusobacterium 13%)

Micro-pathophysiology

- Initial infection by aerobic bacteria. Produces cellulitis without pus-this can spread rapidly-local tissue becomes hypoxic and acidic - anaerobic bacti., then grow, destroying tissue and causing pus production and abscess formation

Imaging

- High-resolution Ultrasound
  - Advantages
    - Avoids radiation
    - Portable
  - Disadvantages
    - Not widely accepted
    - Operator dependent
    - Inferior anatomic detail
  - Uses
    - Following infection during therapy
    - Image guided aspiration

Imaging

- Contrast enhanced CT
  - Advantages
    - Quick, easy
    - Widely available
    - Familiarity
    - Superior anatomic detail
    - Differentiate abscess and cellulitis
  - Disadvantages
    - Ionizing radiation
    - Allergenic contrast agent
    - Soft tissue detail
    - Artifact

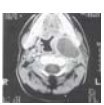

Imaging

- Contrast enhanced CT
  - Modality of choice
  - Miller, et al: CT vs. PE
    - Accuracy of diagnosis: CT = 77%, PE = 63%
    - Sensitivity: CT = 95%, PE = 55%

Infection Management

- Treat surgically
- Remove the source
- Open the involved spaces - drain
- Appropriate Abx coverage
- Medical support and Re-evaluation

Surgical Management

- Extraction vs Total Pulpectomy
- I & D
- Drain placement

Incision & Drainage

- Avoid areas of function
- Incise thru healthy tissue
- Incise in a dependant area
- Incise over bone when possible
- Use blunt dissection
- Always suction and cultures in hand

Drains

- Place in dependant site, to depth of dissection, secure to skin with nonresorbable suture
- If possible place drain in each involved space
- If deep gradually back drain out

I & D and Drains

- Increase blood flow to site
- Change the bacterial population of site
- Decrease the bacterial load at site
- Allow for irrigation of site
- Allow for C & S and Gram staining

Surgical Treatment

- Provide drainage
- Remove the cause of infection
  - Pulpectomy
  - Extraction
  - Remove foreign body
  - Debride non-viable bone
- Culture and sensitivity

Surgical Treatment

- Incision and drainage
  - Dependent site
  - Incision in healthy tissue
  - Adequate drainage
  - Exploration of all involved spaces
  - Irrigation

Surgical Treatment

Indications for Culture and Sensitivity Testing

- Rapidly spreading infection
- Post-op infection
- Non-responsive infection
- Recurrent infection
- Compromised host defenses

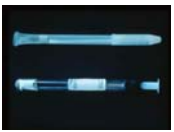

Microbiologic Considerations

- Identification of bacteria
  - Representative specimen collected
  - Examine specimen
  - Submit for culture and sensitivity
  - Gram Stain

Culture and Sensitivity

Principles of Antibiotic Therapy

- Use Empiric Therapy
- Use narrowest spectrum drug
- Use antibiotic with the lowest toxicity
- Use bactericidal antibiotic
- Be aware of Cost $$$

Choosing the Appropriate Antibiotic

- Is an antibiotic necessary?
- Indications:
  - Acute onset infection
  - Diffuse swelling
  - Compromised host defenses
  - Involvement of fascial spaces
  - Severe pericoronitis



Principles of Antibiotic Therapy

- Administer the antibiotic properly
- Proper route of administration
- Proper dose
- Proper time interval
- Adequate period of administration



Antibiotic Cost Comparison

Drug	Dose	Cost for 10 days
• Pen VK	QID	$1.20
• E-mycin	QID	$3.20
• Keflex	QID	$4.00
• Duricef	BID	$37.80
• Cipro	BID	$34.20

Antibiotic Compliance

- Dosage interval that encourages compliance
  - QD or BID 70%
  - QID 40%
- Non-compliant after start feeling better
  - 3-5 days 50%
  - >7 days 20%

Antibiotic Use Indications

- Acute onset
- Diffuse swelling
- Compromised host defenses
- Trismus
- Involved Fascial spaces
- Cardinal signs
  - fever
  - tachycardia

Antibiotic Administration

- Proper Dosage and Interval
- Narrow Range *(ASAP)
- Peak plasma level 4-5 X Minimum Inhibitory Concentration (MIC)
- Continue 2-3d after resolution of infection

Antibiotic Agents

- Penicillin G or V
- Penicillinase Resistant Penicillin
- Clindamycin
- Metronidazole
- Erythromycin
- Ciprofloxacin
- Gentamycin

Ext Spectrum Pens with Clav.

- Augmentin and Timentin
- Spectrum: All anaerobes, Streptococci, meth. Sensitive S.aureus, S.epidermidis, H. Influenzae, Enterococcus
- Pseudomonas aeuruginosa sensitive to ticarcillin

Clindamycin

- Spectrum: Aerobes, Alpha hemolytic Strept, S.aureus, G+ and G- anaerobes (Clostridium, Actinomyces)
- Good bone penetration

Clindamycin

- Mechanism: Bacteriostatic, inhibits protein synthesis by binding to the 50s bacterial ribosomal subunit, Bactericidal at high blood levels
- Adverse Effects: Pseudomembranous colitis (toxin produced by overgrowth of C.difficile)

Clindamycin

- Dose: PO 150-450mg q6h
  IV150-900mg q6-8h

Metronidazole

- Spectrum: G- and obligate anaerobes including Bacteroides fragilis
- Mechanism: Bactericidal (in bacti cell wall chemical reduction produces cytoxic product)
- Doesn't cross blood brain barrier

Metronidazole

- Adverse effects: Convulsive seizures, n/v, peripheral neuropathy, diarrhea, reversible neutropenia, rash, pruritis
- Dose: PO 500mg TID
  IV15mg/kg load 7.5mg/kg q6h

Development of an adverse reaction?

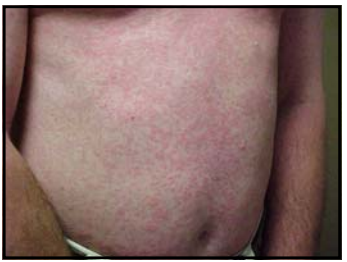

CASE #1

CASE #1

CASE #1

QUESTIONS ???